

CASE REPORT

Management of Traumatic Liver and Bile Duct Laceration

¹Charu Tiwari, ¹Hemanshi Shah, ¹Mukta Waghmare, ¹Kiran Khedkar, ¹Pankaj Dwivedi

¹Department of Paediatric Surgery, Topiwala National Medical College & BYL Nair Charitable Hospital, Mumbai, Maharashtra, India

ABSTRACT

Posttraumatic major bile leak in children is uncommon, with few cases reported in the literature. These injuries are seen in high-grade liver trauma and are difficult to diagnose and manage. We describe a 7-year-old boy with grade IV hepatic trauma and bile leak following blunt abdominal trauma. The leak was successfully managed by percutaneous drainage and endoscopic retrograde cholangiopancreatography (ERCP) stenting of the injured hepatic duct.

Keywords: Bile leak, Biloma, Hepatic trauma.

How to cite this article: Tiwari C, Shah H, Waghmare M, Khedkar K, Dwivedi P. Management of Traumatic Liver and Bile Duct Laceration. *Euroasian J Hepato-Gastroenterol* 2017;7(2):188-190.

Source of support: Nil

Conflict of interest: None

INTRODUCTION

The incidence of biliary complications after blunt hepatic trauma has been reported to be 2.8 to 7.4%.¹⁻³ Such complications are usually seen in high-grade liver injuries and are more complex unlike postoperative iatrogenic injuries.⁴ The management of these injuries requires a high index of clinical suspicion, timely and correct diagnosis, and appropriate treatment.^{4,5} This reduces complications and helps in rapid recovery of the patient.

CASE SUMMARY

A 7-year-old boy was brought with trauma to head, right upper limb, and abdomen due to a road traffic accident. At admission, he had tachycardia and hypotension. Glasgow Coma Scale score was 15/15. Abdomen was distended with tenderness and guarding in the right hypochondrium. He was resuscitated by administration of crystalloids and colloids.

Abdominal sonography revealed gross hemoperitoneum with liver laceration in segments III and IV along with splenic laceration. Contrast-enhanced computed tomography (CECT) abdomen suggested massive hemoperitoneum with American Association for the Surgery of Trauma (AAST) grade IV trauma in segments III and IV of liver and AAST grade I trauma in spleen (Fig. 1). Bowel was normal. There was no pneumoperitoneum. The CT thorax was unremarkable. The right humeral

fracture was managed with a cast. The patient was kept under strict observation with regular monitoring of vitals. Blood was transfused.

Patient's vitals stabilized. He tolerated oral diet and was opening bowel regularly. However, he continued to have persistent abdominal distention for 5 days after the injury. Repeat ultrasonography showed massive fluid collection with moving echoes and septae. Biliary ooze from the lacerated liver edge was suspected. Aspiration confirmed golden yellow bile. Ultrasound-guided pig tail for external drainage was inserted and 1,000 cc bile was drained. Bile drainage continued to be constant at 300 cc per day. The ERCP revealed left hepatic duct injury which was stented with 7 French stent (Fig. 2). External drain was removed after decrease in output. The patient recovered well. Stent was removed after 6 weeks.

DISCUSSION

Complications are mostly seen in high-grade liver injuries.^{4,6} Such complications can be bile leak, liver abscess, and ischemic necrosis of the liver and gallbladder.⁴ Injuries to the biliary tract after blunt abdominal trauma can be classified as intra- or extrahepatic. Extrahepatic bile duct injury may occur in the absence of a liver parenchymal injury, whereas intrahepatic bile duct injury is invariably associated with liver parenchymal laceration.^{4,7} These injuries can be simple bile leaks into the lacerated liver, peritoneal cavity, or pleural cavity or even biliary-vascular fistulae.^{4,8}

Address reprint requests to: Hemanshi Shah, Department of Paediatric Surgery, Topiwala National Medical College & BYL Nair Charitable Hospital, Mumbai, Maharashtra, India, Phone: +912223027671, e-mail: hemanshishah@gmail.com

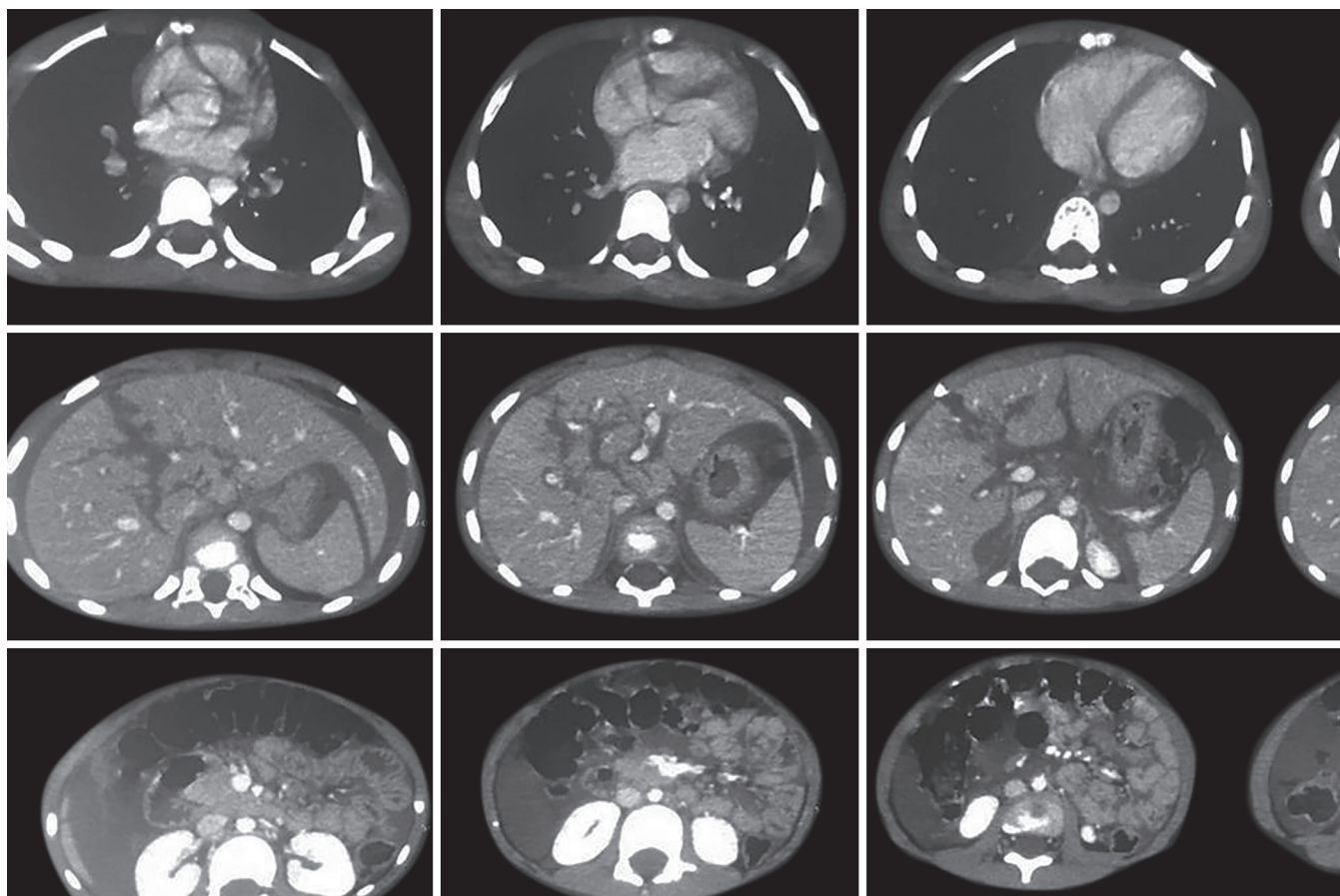
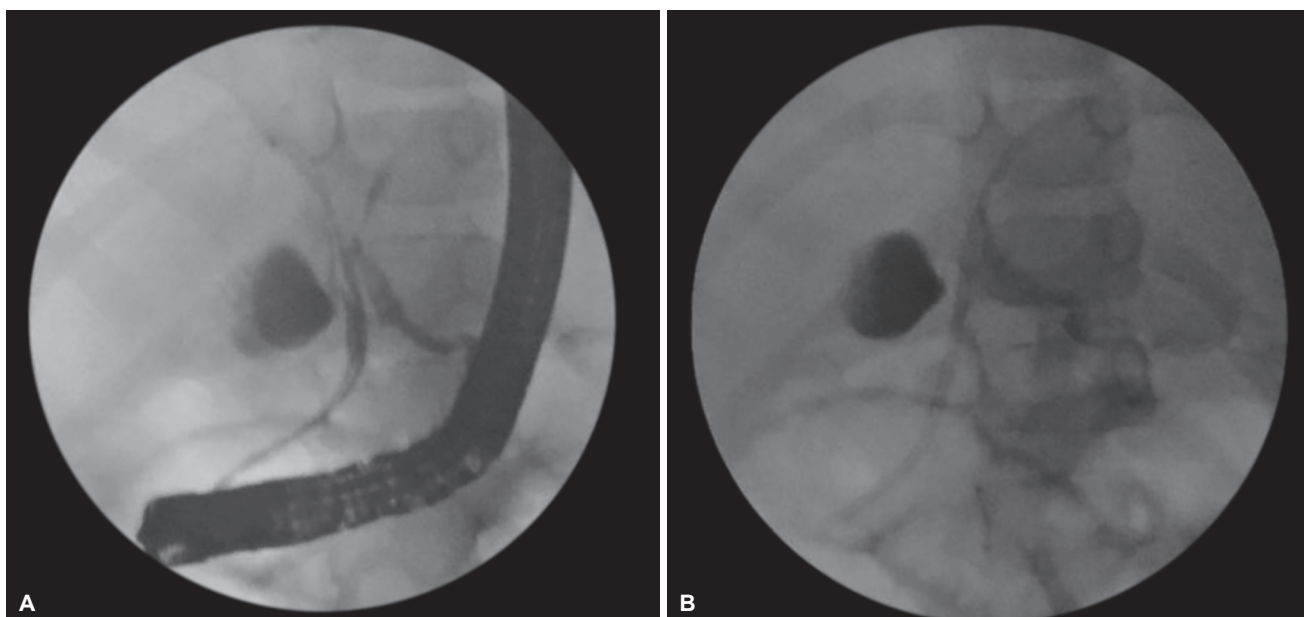


Fig. 1: Contrast-enhanced computed tomography of abdomen showing massive hemoperitoneum with AAST grade IV trauma in segments III and IV of liver and AAST grade I trauma in spleen



Figs 2A and B: Endoscopic retrograde cholangiopancreatography showing bile leak from left hepatic duct

The appearance of clinical signs and symptoms like right upper quadrant pain, jaundice, fever, or malena indicates liver-related complications.¹ Studies in literature show that the optimal time period from injury to appearance of complications in high-grade liver injuries is 7 to

10 days.¹ A repeat CECT scan has been recommended during this time period in symptomatic patients with high-grade liver trauma.¹ The CECT suggests biloma as progressive growth of a well-circumscribed, low-attenuation intraparenchymal or perihepatic collection.^{1,9}

However, though the presence of free fluid is sensitive, it is nonspecific for bile leak.^{4,10} Delayed bile leaks have also been reported to occur following a secondary rupture of a subcapsular collection or due to duct ischemia.^{4,7} For asymptomatic patients with low-grade liver injuries, a repeat CECT is generally unnecessary.^{1,11}

The ERCP with stenting coupled with percutaneous drainage is the mainstay of therapy for the treatment of major bile leaks in patients with high-grade liver trauma.¹ Endoscopic techniques that are used to manage bile leaks include biliary sphincterotomy alone, biliary stenting with or without sphincterotomy, and nasobiliary drainage with or without sphincterotomy to allow internal drainage of bile and reduction in intrabiliary pressure that would help the bile duct injury to seal off.^{4,12} Wahl et al¹³ have suggested that patients sustaining high-grade hepatic injury were more likely to have bile leaks.⁴ It has been recommended that continuous high-output biliary drainage should be managed by ERCP and stenting to allow for healing.¹ Marks et al¹⁴ have suggested that stenting, rather than sphincterotomy was more effective in resolving biliary leaks.¹ On the contrary, most of the minor peripheral biliary leaks usually seal spontaneously without any intervention.¹

The success rate for ERCP and stenting ranges from 90 to 100%.^{1,15-17} Sugimoto et al,¹⁸ Bajaj et al,¹⁹ and Bala et al¹ have reported success of ERCP in blunt hepatic trauma-related biliary leaks. Nonoperative treatment of biliary complications is associated with little or no long-term morbidity.

REFERENCES

- Bala M, Gazalla SA, Faroja M, Bloom AI, Zamir G, Rivkind AI, Almogy G. Complications of high grade liver injuries: management and outcome with focus on bile leaks. *Scand J Trauma Resusc Emerg Med* 2012 Mar;20:20.
- Kozar RA, Moore JB, Niles SE, Holcomb JB, Moore EE, Cothren CC, Hartwell E, Moore FA. Complications of non-operative management of high-grade blunt hepatic injuries. *J Trauma* 2005 Nov;59(5):1066-1071.
- Carrillo EH, Spain DA, Wohltmann CD, Schmiege RE, Boaz PW, Miller FB, Richardson JD. Interventional techniques are useful adjuncts in nonoperative management of hepatic injuries. *J Trauma* 1999 Apr;46(4):619-622.
- Al-Hassani A, Jabbour G, ElLabib M, Kanbar A, El-Menyar A, Al-Thani H. Delayed bile leak in a patient with grade IV blunt liver trauma: a case report and review of the literature. *Int J Surg Case Rep* 2015 Aug;14:156-159.
- Navaneethan U, Jayanthi V. Endoscopic management of biliary leaks: the answer for the future. *Minerva Gastroenterol Dietol* 2008 Jun;54(2):141-150.
- Pachter HL, Knudson MM, Esrig B, Ross S, Hoyt D, Cogbill T, Sherman H, Scalea T, Harrison P, Shackford S, et al. Status of nonoperative management of blunt hepatic injuries in 1195: a multicenter experience with 404 patients. *J Trauma*. 1996 Jan;40(1):31-38.
- Sharma BC, Mishra SR, Kumar R, Sarin SK. Endoscopic management of bile leaks after blunt abdominal trauma. *J Gastroenterol Hepatol* 2009 May;24(5):757-761.
- Castagnetti M, Houben C, Patel S, Devlin J, Harrison P, Karani J, Heaton N, Davenport M. Minimally invasive management of bile leaks after blunt liver trauma in children. *J Pediatr Surg* 2006 Sep;41(9):1539-1544.
- De Backer A, Fierens H, De Schepper A, Pelckmans P, Jorens PG, Vaneerdeweg W. Diagnosis and nonsurgical management of bile leak complicated by biloma after blunt liver injury: report of two cases. *Eur Radiol* 1998 Feb;8(9):1619-1622.
- LeBedis CA, Anderson SW, Mercier G, Kussman S, Coleman SL, Golden L, Penn DR, Uyeda JW, Soto JA. The utility of CT for predicting bile leaks in hepatic trauma. *Emerg Radiol* 2015 Apr;22(2):101-107.
- Cuff RF, Cogbill TH, Lambert PJ. Nonoperative management of blunt liver trauma: the value of follow-up abdominal computed tomography scans. *Am Surg* 2000 Apr;66(4):332-336.
- Harrell DJ, Vitale GC, Larson GM. Selective role for endoscopic retrograde cholangiopancreatography in abdominal trauma. *Surg Endosc* 1998 May;12(5):400-404.
- Wahl WL, Brandt MM, Hemmila MR, Arbabi S. Diagnosis and management of bile leaks after blunt liver injury. *Surgery* 2005 Oct;138(4):742-747.
- Marks JM, Ponsky JL, Shillingstad RB, Singh J. Biliary stenting is more effective than sphincterotomy in the resolution of biliary leaks. *Surg Endosc* 1998 Apr;12(4):327-330.
- Singh V, Narasimhan KL, Verma GR, Singh G. Endoscopic management of traumatic hepatobiliary injuries. *J Gastroenterol Hepatol* 2007 Aug;22(8):1205-1209.
- Hassan MAG, Kabeer SA, Nur AM. Unusual right hepatic bile duct injury following blunt abdominal trauma. *Kuwait Med J* 2001;33:59-61.
- Lubezky N, Konikoff FM, Rosin D, Carmon E, Kluger Y, Ben-Haim M. Endoscopic sphincterotomy and temporary internal stenting for bile leaks following complex hepatic trauma. *Br J Surg* 2006 Jan;93(1):78-81.
- Sugimoto K, Asari Y, Sakaguchi T, Owada T, Maekawa K. Endoscopic retrograde cholangiography in the nonsurgical management of blunt liver injury. *J Trauma* 1993 Aug;35(2):192-199.
- Bajaj JS, Spinelli KS, Dua KS. Postoperative management of noniatrogenic traumatic bile duct injuries: role of endoscopic retrograde cholangiopancreatography. *Surg Endosc* 2006 Jun;20(6):974-977.