

# Amyand's Hernia as a Sliding Component of a Right Congenital Indirect Inguinal Hernia: A Case Report and Review of Literature

Ambikavathy Mohan, PN Sriramulu

## ABSTRACT

Amyand's hernia is the presence of vermiform appendix in the inguinal hernia sac. Amyand's hernia is rare, occurring in about 1% of inguinal hernias. We report a case of 22 years male patient with right congenital inguinoscrotal, complete, reducible hernia. He underwent elective transherniotomy, appendicectomy and hernioplasty with an uneventful postoperative recovery.

**Keywords:** Amyand's hernia, Appendiceal sliding hernia, Inguinal hernia.

**How to cite this article:** Mohan A, Sriramulu PN. Amyand's Hernia as a Sliding Component of a Right Congenital Indirect Inguinal Hernia: A Case Report and Review of Literature. *Euroasian J Hepato-Gastroenterol* 2013;3(2):132-133.

**Source of support:** Nil

**Conflict of interest:** None

## INTRODUCTION

Hernia is defined as the abnormal protrusion of a viscous or a part of it through the wall of its containing cavity. Inguinal hernia may have unusual sac contents such as ovary, urinary bladder, ovary and fallopian tubes, small bowel, colon, etc.<sup>1</sup> The presence of vermiform appendix as a sliding component is rare. Presence of appendix in the inguinal hernia sac is called as Amyand's hernia, and has an incidence of 1%. The appendix as a sliding component is more rarer.<sup>2</sup> Amyand's hernia is named for appendiceal hernia in honor of Claudius Amyand who in 1735 first reported the presence of a perforated appendix in the inguinal hernia sac and he had performed transherniotomy appendectomy.<sup>3</sup> We report a case of Amyand's hernia, who underwent transherniotomy appendicectomy and hernioplasty. He had an uneventful postoperative period.

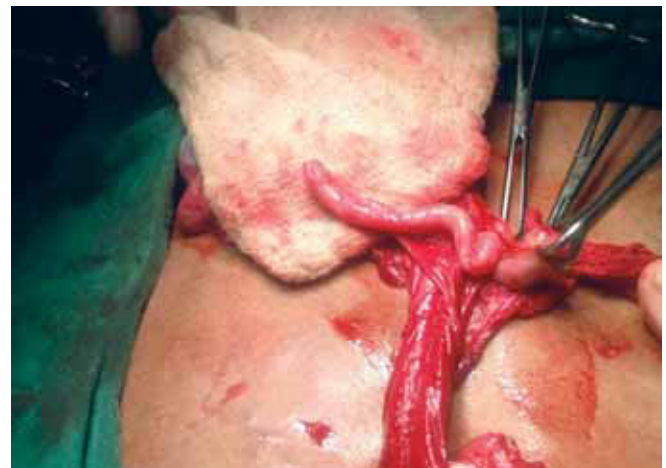## CASE REPORT

A 22 years male patient presented to our outpatient department with a large right inguinoscrotal swelling which he had from the last 6 years. He had a small swelling in the same side in the inguinal region from his childhood and from the last 6 years he had noticed increase in the size of the swelling, reaching up to the scrotum on doing his routine work, which is associated with dragging pain in the groin. We diagnosed it as right inguinoscrotal, indirect, complete, reducible hernia with enterocele as content; an elective conventional hernia repair under spinal anesthesia was

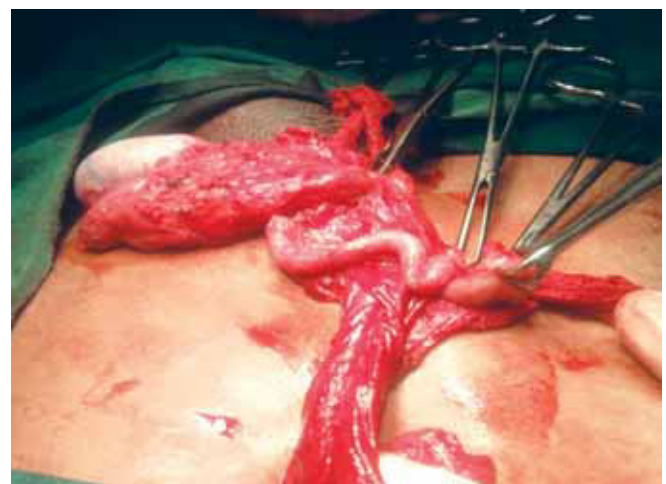
planned. On conventional right inguinal incision for hernia repair, the sac contents displayed cecum and appendix as a sliding component with appendix adherent all along the long sac. The bowel and appendix appeared normal. The appendix measured 9 cm in length (Figs 1 to 4). Transherniotomy appendicectomy was performed followed by Lichtenstein's tension free hernioplasty. The patient was covered with broad spectrum antibiotics/analgesics. Postoperative recovery was uneventful.

## DISCUSSION

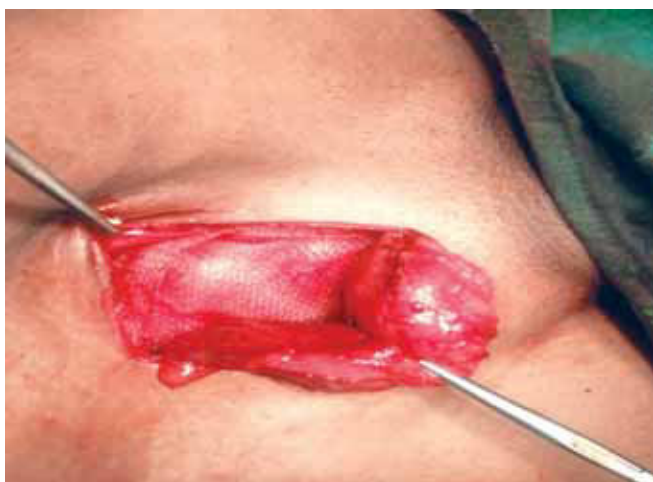Large or huge inguinoscrotal hernias are usually sliding hernias with cecum and bladder on the right and descending



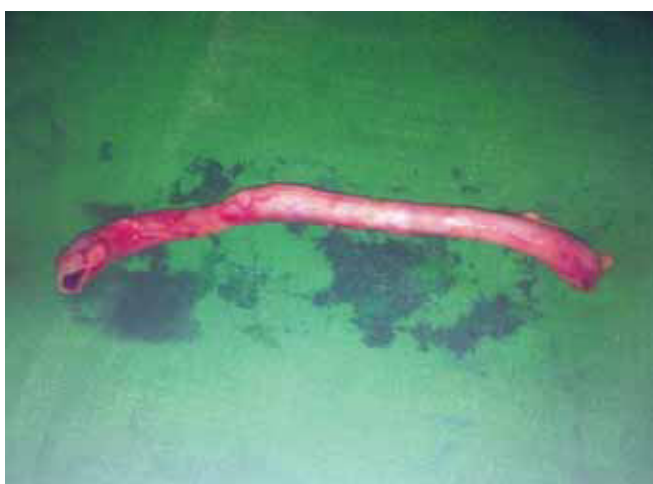**Fig. 1:** Intraoperative photograph showing appendix and cecum as contents in the hernia sac



**Fig. 2:** Intraoperative photograph showing appendix adherent all along the sac



**Fig. 3:** Operative photograph showing tension free meshplasty completed



**Fig. 4:** Photograph showing specimen of appendix (9 cm)

colon or urinary bladder on the left. One should suspect the presence of appendix in such conditions, although it is rare.<sup>1,2</sup> Usually, surgeons proceed with surgery only with a clinical diagnosis for inguinal hernias unless otherwise a complication is suspected as in strangulated or obstructed hernias. Amyand's hernia is usually an intraoperative finding. A preoperative ultrasonography and CT abdomen could complement in such cases, though it is routinely not practiced when a clinical diagnosis of inguinal hernia is evident.<sup>2-4</sup> The presence of adhesion of appendix to the sac could be attributed to the congenital inguinal hernia with the patent processes vaginalis.<sup>2,4</sup> Although, most of the authors prefer not to do an appendicectomy in an Amyand's hernia as it can add to contamination of an otherwise clean field and recurrence.<sup>5</sup> In our case, after reducing the hernia by conventional approach the appendix was adherent all along the sac, therefore it was inevitable for us to perform appendicectomy though it appeared

normal. Acute appendicitis in an inguinal hernia usually mimics an obstructed or strangulated hernia or hollow viscous perforation within the hernia sac.<sup>6,7</sup> Amyand's hernia is more common on the right as the hernias are more on right than left.<sup>8</sup> Our patient underwent transherniotomy appendicectomy with hernioplasty with uneventful postoperative recovery.

## CONCLUSION

Appendix as a content should be kept in mind in large hernias. A routine ultrasound examination preoperatively could complement the diagnosis. The surgical preference of transherniotomy appendectomy with hernioplasty in normal incidental appendix and appendectomy with herniorrhaphy for perforated appendix/appendicitis in the hernia sac depends on the intraoperative findings at time of surgery.

## REFERENCES

1. Gurer A, Ozdogan M, Ozlem N, Yildirim A, Kulacoglu H, Aydin R. Uncommon content in groin hernia sac. *Hernia* 2006 Apr;10(2):152-155.
2. Oguzkurt P, Kayaselcuk F, Oz S, Arda IS, Oguzkurt L. Sliding appendiceal inguinal hernia with a congenital fibrovascular band connecting the appendix vermiformis to the right testis. *Hernia* 2001 Sep;5(3):156-157.
3. Hutchinson R. Amyand's hernia. *J R Soc Med* 1993 Feb;86(2):104-105.
4. Celik K, Ergun O, Ozbek SS, Dokumcu Z, Balik E. Sliding appendiceal inguinal hernia: preoperative sonographic diagnosis. *J Clin Ultrasound* 2003 Mar-Apr;31(3):156-158.
5. Karatas A, Makay O, Salihoglu Z. Can preoperative diagnosis affect the choice of treatment in Amyand's hernia? Report a case of hernia. *Hernia* 2008 Apr;13(2):225-227.
6. Anagnostopoulou S, Dimitroulis D, Troupis TG, Allamani M, Paraschos A, Mazarakis A, Nikiteas NI, Kostakis A. Amyand's hernia: a case report. *World J Gastroenterol* 2006 Aug;12(29):4761-4763.
7. Nigri G, Costa G, Valabrega S, Aurello P, D'Angelo F, Bellagamba R, Lauro A, Ramacciato G. A rare presentation of Amyand's hernia. Case report and review of literature. *Minerva Chir* 2008 Apr;63(2):169-174.
8. Pellegrino JM, Feldman SD. Case report: acute appendicitis in an inguinal hernia. *N J Med* 1992 Mar;89(3):225-226.

## ABOUT THE AUTHORS

### Ambikavathy Mohan (Corresponding Author)

Associate Professor, Department of Surgery, Sri Devaraj Urs Medical College, Kolar, Karnataka, India, Phone: 9980337428 e-mail: ambikaashri67@live.com

### PN Sriramulu

Professor, Department of Surgery, Sri Devaraj Urs Medical College Kolar, Karnataka, India