

# B-RTO for Gastric Varices

Hitoshi Maruyama, Osamu Yokosuka

## ABSTRACT

Gastric varices (GV) are considerable hemodynamic abnormality in patients with portal hypertension. Recent developments in both imaging technology and medical devices have made it possible to perform various radiological techniques. Balloon-occluded retrograde transvenous obliteration (B-RTO) is an interventional technique which provides high success rate of GV embolization with less recurrence. This review article aimed to introduce the concept and technique of B-RTO, and overview the effect and outcome of the treatment.

**Keywords:** Gastric varices, Balloon-occluded retrograde transvenous obliteration, Portal hypertension.

**How to cite this article:** Maruyama H, Yokosuka O. B-RTO for Gastric Varices. *Euroasian J Hepato-Gastroenterol* 2013; 3(1):54-58.

**Source of support:** Nil

**Conflict of interest:** None

## INTRODUCTION

Gastric varices (GV) are considerable hemodynamic abnormality in patients with portal hypertension.<sup>1</sup> Approximately 20 to 25% of patients with cirrhosis/portal hypertension have GV.<sup>2,3</sup> Although it is reported that bleeding rate was lower in GV than esophageal varices, bleeding from GV may have a risk of causing serious consequences.<sup>4,5</sup> Actually, variceal bleeding is a major cause of mortality in cirrhotic patients.<sup>6</sup>

Endoscopic treatment may be the technique most frequently used for the treatment of GV.<sup>7-9</sup> It is effective to achieve hemostasis in the emergency bleeding cases. However, the effects are not always sufficient as a curative treatment method in the long period.

Balloon-occluded retrograde transvenous obliteration (B-RTO) is an interventional technique which provides high success rate of GV embolization with less recurrence. It was introduced by Kanagawa et al in 1991,<sup>10</sup> and some technical improvements have been added since then.<sup>11-13</sup> Investigators have shown the effectiveness of this technique for the treatment of GV and shunt-related hepatic encephalopathy.<sup>14,15</sup> This review article aimed to introduce the concept and technique of B-RTO, and overview the effect and outcome of the treatment.

## CONCEPT OF B-RTO

### Anatomy of GV

GV and esophageal varices are located in the different depth in the gastrointestinal wall, as the former deeply in the

submucosa and the latter in the lamina propria mucosa and submucosa.<sup>16</sup>

Hemodynamic features are also different between these two varices. As for the inflow route, although the left gastric vein is a major pathway to esophageal varices, short gastric vein and/or posterior gastric vein are known as major inflow routes for GV.<sup>17,18</sup> Meanwhile, the main outflow route of esophageal varices is azygos vessel, while that of the majority of GV is the gastrosplenic shunt. It is reported that more than 80% patients with GV have gastrosplenic shunt as a drainage route,<sup>17</sup> and the grade of gastrosplenic shunt depends on the severity of the GV.<sup>19</sup> B-RTO is a technique to embolize collateral vessels under the control of blood flow in the outflow route (Fig. 1).

### Application

A secondary prophylaxis is a reasonable application of B-RTO. Although a previous study reported the efficacy of emergency B-RTO in patients with GV bleeding, all the subjects in the study underwent B-RTO after hemostasis had been achieved.<sup>20</sup> In fact, as B-RTO needs control of blood flow in the outflow route of GV, it may have negative effect for attaining hemostasis of GV. Elective B-RTO may be preferable after the stability of the patient condition.

Primary prophylaxis is sometimes performed in the limited countries, though scientific evidence is lacking. A prospective study with a large number of patients may be required to determine the appropriate application of B-RTO for GV.

## PROCEDURE OF B-RTO

### Anesthesia and Sclerosant

Intravenous or intramuscular sedation may be effective as a pre-B-RTO preparation. Also, local anesthesia is needed for the puncture site, jugular vein or inguinal vein. Ethanamine oleate (10%) is necessary for sclerosing agent. Recommended maximum amount of the agent per one treatment is 20 ml. The agent should be injected to varices as a 5% solution that contains equal amounts of 10% ethanamine oleate and iodinated contrast medium. Administration of haptoglobin (200 ml; Mitsubishi Tanabe, Osaka, Japan) is effective to prevent hemolysis caused by ethanamine oleate.

### Procedure for B-RTO

Blood flow in the outflow route of GV, which is a gastrosplenic shunt in the most of cases, needs to be controlled by

retrograde manner using balloon catheter inserted in the shunt vessel. The size of balloon should be selected according to the diameter of the vessel. Advancement of the catheter to the distal position under the guidance by guidewire may be effective to reduce the amount of sclerosant.

Next, retrograde venography is required to demonstrate the GV under the occlusion of the shunt by inflated balloon (Fig. 2). This image also help estimate the total amount of sclerosant to fill up the variceal route. Using an oral uptake of expanding agent may be effective to provide the anatomical landmark for GV on the venogram. If the varices are not fully detected, location of balloon catheter should be moved or the other communicating vessels need to be embolized by coiling. When GV are detected, it is ready to inject the sclerosing agent (5% solution) to fill up GV under the fluoroscopy.

### Period for Balloon Occlusion

Balloon occlusion allows it to keep the sclerosant within the varices, resulting in the endothelial damage of the vessel. Previous study examined the effect of 1 hour occlusion method, showing complete embolization in 88.2% of moderate or large GV.<sup>13</sup> The study reported that varices with higher inflow volume were not eradicated by 1 hour method, requiring second B-RTO. Overnight occlusion may be effective in such cases.<sup>15,21,22</sup>

### Evaluation of Therapeutic Effect

The therapeutic effect by B-RTO is usually assessed by contrast-enhanced CT or Doppler sonography (Figs 3A and B). No enhancement or no color signal in the varices suggests successful treatment which leads to complete

eradication of GV (Fig. 4A and B). Protruded appearance at the variceal site by endoscopy may remain a few months.

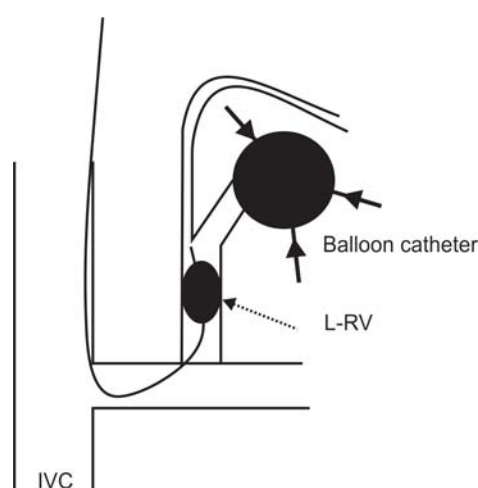
## EFFECT AND OUTCOME OF B-RTO

### Embolization of GV

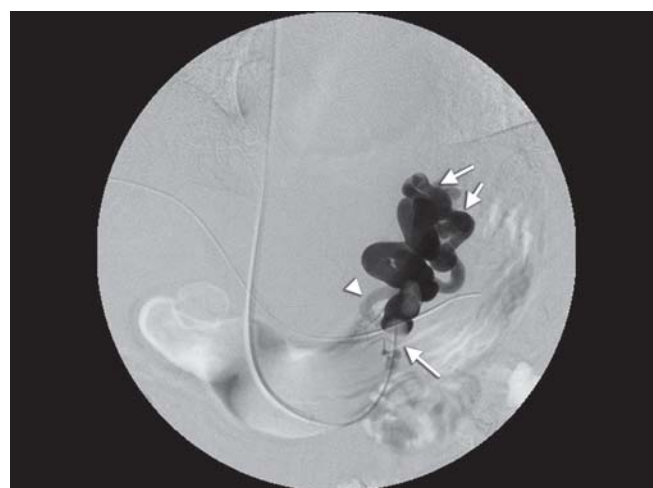If the procedures are successfully performed, B-RTO eradicates GV in the majority of patients (Table 1).<sup>10,15,22,23</sup> The effect for variceal embolization may depends on the grade of GV determined by portal hemodynamics.<sup>13,24</sup> Okugawa et al reported that flow velocity and flow volume in the short gastric vein which is a major inflow route for GV before initial B-RTO were significantly lower in 27 patients with complete effect ( $7.19 \pm 2.44$  cm/s,  $p = 0.0246$ ;  $189.52 \pm 167.66$  ml/min,  $p = 0.002$ ) than in seven patients with incomplete effect ( $10.41 \pm 5.44$  cm/s,  $492.14 \pm 344.94$  ml/min). Evaluation of pretreatment portal hemodynamics by Doppler ultrasonography may be useful for the prediction of the therapeutic effect of B-RTO. Previous studies have shown that recurrence of GV after successful B-RTO is rare (Table 1).

### Changes of Liver Function and Portal Hemodynamics

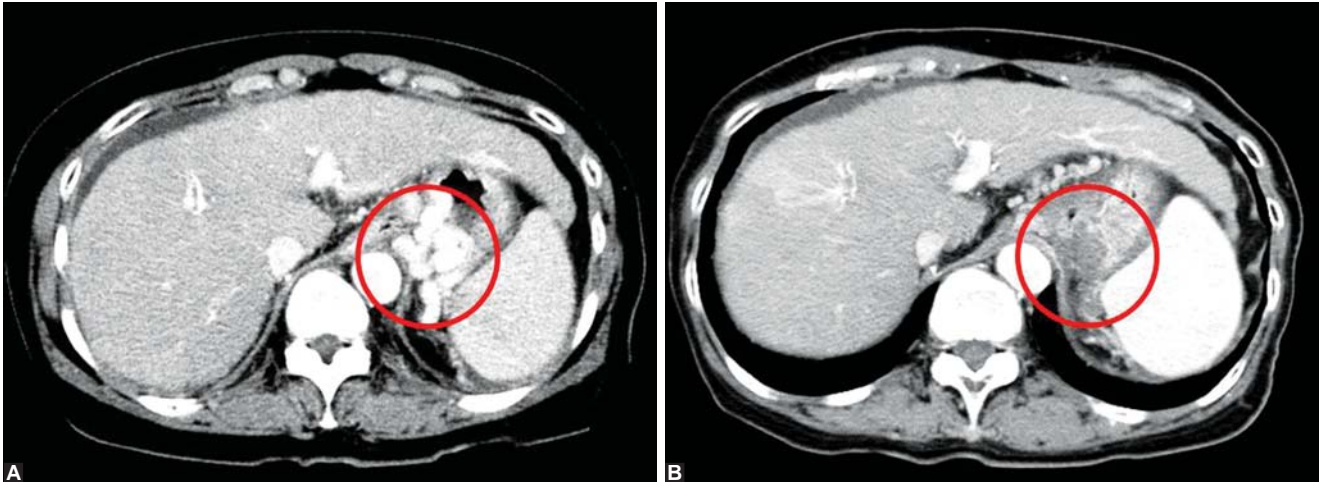
Akahane et al reported that portal blood flow significantly increased from  $5.4 \pm 1.1$  to  $7.85 \pm 1.4$  cm/s and that the indocyanine green retention rate significantly improved from  $31.8 \pm 16.1$  to  $21.8 \pm 12.4\%$  in GV patients after B-RTO.<sup>25</sup> However, they also found a significant increase in portal venous pressure from  $25.4 \pm 7.6$  to  $30.7 \pm 5.8$  mm H<sub>2</sub>O, as this technique has an opposite effect to the decompressive treatment like transjugular intrahepatic portosystemic shunt. Thus, care should be taken for the



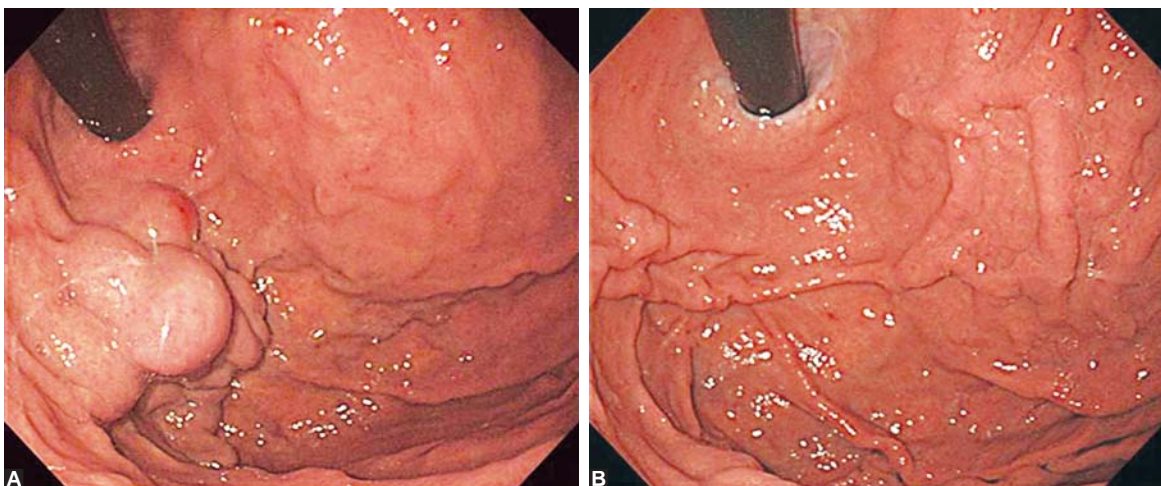
**Fig. 1:** Schema for B-RTO, blood flow in the outflow route of gastric varices was occluded by balloon catheter (arrow with dotted line). Gastric varices (circle; arrows, inflow routes for GV) were embolized by sclerosant injected by retrograde manner from balloon catheter



**Fig. 2:** Balloon-occluded retrograde venogram for GV, thick arrow, GV, thin arrow, balloon catheter, arrow heads, inflow route (posterior gastric vein)



**Figs 3A and B:** Contrast-enhanced CT images of GV (circle): (A) Before B-RTO, (B) after B-RTO



**Figs 4A and B:** Endoscopic appearances of GV: (A) Before B-RTO, (B) after B-RTO

deterioration of esophageal varices as a long-term complication after B-RTO.

### Prognosis

Several studies have reported the long-term prognosis of the patients after B-RTO; 76% at 3 years and 54% at 5 years by Ninoi et al,<sup>21</sup> 68% at 5 years by Hiraga et al,<sup>26</sup> 76% at 3 years, 61% at 5 years and 47% at 8 years by Chikamori et al,<sup>22</sup> 90% at 1 year, 74.8% at 3 years, 57.2% at 5 years, and 45.8% at 7 years by Maruyama et al.<sup>15</sup> In Child-Pugh class B or C patients, the cumulative survival rate was poorer in patients with reversed portal flow at baseline (68.7, 30.5 and 30.5% at 1, 5 and 9 years, respectively) than in patients without that (94.9, 58.8 and 37.8% and 1, 5 and 9 years, respectively;  $p = 0.0097$ ).<sup>27</sup> In general, survival rate may be satisfactory, though it is influenced by the accompanying liver disease such as cirrhosis. Presence of hepatocellular carcinoma, liver function, and grade of portal hemodynamics at baseline are significant factors which determine their prognosis.<sup>15,22,27</sup>

### Complications

Minor events, such as fever, pain and hemoglobinuria, are common complications after B-RTO.<sup>13,28</sup> Most of the patients recover from them within a couple of days. An adequate hydration by drip infusion on the day is important to avoid renal dysfunction. Shock, renal failure, disseminated intravascular coagulation are rare but possible complications.<sup>27,28</sup> Thrombotic disorders within 1 year after B-RTO were also more frequent in patients with reversed portal flow at baseline (20.7%) than in patients without that (2.7%,  $p = 0.0079$ ).<sup>27</sup> In the long-term clinical course, a worsening rate of esophageal varices is reported in 50% or more,<sup>15,21,27</sup> suggesting a need for careful follow-up by endoscopy after B-RTO.

### Technical Improvement

There are some technical improvements in B-RTO. Selective embolization may have a potential to reduce the amount of sclerosant, and preserve the major shunt for a prevention of

Table 1: Effect of B-RTO for gastric varices

Patient number	Disappearance	Recurrence	Balloon occlusion	Author (Journal)
32	96.9% (31/32)	None	30 mins	Kanagawa et al (JGH 1996)
52	100% (52/52)	None	Over night or more	Chikamori et al (Surgery 2001)
30	100% (30/30)	10% (3/30)	30 mins	Koito et al (AJR 1996)
20	75% (15/20)	None	1-3 hours	Hirota et al (Radiology 1999)
34	88.2% (30/34) (3 by second B-RTO)	None	1 hour	Okugawa et al (BJR 2009)

treatment-related increase of portal pressure.<sup>29</sup> Addition of partial splenic embolization may also reduce the portal pressure after B-RTO.<sup>30</sup> Recent studies have shown that use of 'foam' made by 3% povidocanol, air and contrast media may lower the risk of complications by reducing the dose of contrast medium and sclerosant.<sup>31,32</sup>

## SUMMARY

Recent advancements in medical technologies have resulted in the development of diagnosis and treatments for GV. B-RTO is an effective technique for the curative treatment of GV with less invasive than percutaneous transhepatic obliteration or surgical procedures. However, there are still some problems, lack of scientific evidence of B-RTO in the randomized controlled trial, difficult availability of medical devices and sclerosant in some countries. Continuous efforts may be required to solve these problems.

## REFERENCES

- Bosch J, Abraldes JG, Groszmann R. Current management of portal hypertension. *J Hepatol* 2003;38:S54-68.
- Sarin SK, Lahoti D, Saxena SP, et al. Prevalence, classification and natural history of gastric varices: A long-term follow-up study in 568 portal hypertension patients. *Hepatology* 1992;16:1343-49.
- Kim T, Shijo H, Kokawa H, et al. Risk factors for hemorrhage from gastric fundal varices. *Hepatology* 1997;25:307-12.
- Ryan BM, Stockbrugger RW, Ryan JM. A pathophysiologic, gastroenterologic and radiologic approach to the management of gastric varices. *Gastroenterology* 2004;126:1175-89.
- Lubel JS, Angus PW. Modern management of portal hypertension. *Intern Med J* 2005;35:45-49.
- Williams SG, Westaby D. Management of variceal haemorrhage. *BMJ* 1994;308:1213-17.
- Sarin SK, Kumar A. Gastric varices: Profile, classification and management. *Am J Gastroenterol* 1989;84:1244-49.
- Sarin SK, Sachdev G, Nanda R, et al. Endoscopic sclerotherapy in the treatment of gastric varices. *Br J Surg* 1988;75:747-50.
- Shiha G, El-Sayed SS. Gastric variceal ligation: A new technique. *Gastrointest Endosc* 1999;49:437-41.
- Kanagawa H, Mima S, Kouyama H, et al. Treatment of gastric fundal varices by balloon-occluded retrograde transvenous obliteration. *J Gastroenterol Hepatol* 1996;11:51-58.
- Chikamori F, Shibuya S, Takase Y, et al. Transjugular retrograde obliteration (TJO) for gastric varices. *Abdom Imaging* 1996;21:299-303.
- Tanoue S, Kiyosue H, Matsumoto S, et al. Development of new coaxial balloon catheter system for B-RTO. *Cardiovasc Intervent Radiol* 2006;29:991-96.
- Okugawa H, Maruyama H, Kobayashi S, Yoshizumi H, Matsutani S, Yokosuka O. Therapeutic effect of balloon-occluded retrograde transvenous obliteration for gastric varices in relation to hemodynamics in the short gastric vein. *Br J Radiol* 2009;82:930-35.
- Miyamoto Y, Oho K, Kumamoto M, Toyonaga A, Sata M. Balloon-occluded retrograde transvenous obliteration improves liver function in patients with cirrhosis and portal hypertension. *J Gastroenterol Hepatol* 2003;18:934-42.
- Maruyama H, Okugawa H, Kobayashi S, Yoshizumi H, Yokosuka O. Pretreatment hemodynamic features involved with long-term survival of cirrhotic patients after embolization of gastric fundal varices. *Eur J Radiol* 2010;75:e32-37.
- Arakawa M, Masuzaki T, Okuda K. Pathomorphology of esophageal and gastric varices. *Semin Liver Dis* 2002;22:73-82.
- Watanabe K, Kimura K, Matsutani S, et al. Portal hemodynamics in patients with gastric varices: A study in 230 patients with esophageal and/or gastric varices using portal vein catheterization. *Gastroenterology* 1988;95:434-40.
- Kimura K, Ohto M, Matsutani S, et al. Relative frequencies of portosystemic pathways and renal shunt formation through the posterior gastric vein: Portographic study in 460 patients. *Hepatology* 1990;12:725-28.
- Maruyama H, Okugawa H, Yoshizumi H, Kobayashi S, Yokosuka O. Hemodynamic features of gastrosplenic shunt: A Doppler study in cirrhotic patients with gastric fundal varices. *Acad Radiol* 2008;15:1148-54.
- Arai H, Abe T, Shimoda R, et al. Emergency B-RTO for gastric varices. *J Gastroenterology* 2005;40:964-71.
- Ninoi T, Nishida N, Kaminou T, et al. Balloon-occluded retrograde transvenous obliteration of gastric varices with gastrosplenic shunt: Long-term follow-up in 78 patients. *AJR Am J Roentgenol* 2005;184:1340-46.
- Chikamori F, Kuniyoshi N, Shibuya S, Takase Y. Eight years of experience with transjugular retrograde obliteration for gastric varices with gastrosplenic shunts. *Surgery* 2001;129:414-20.
- Koito K, Namieno T, Nagakawa T, Morita K. Balloon-occluded retrograde transvenous obliteration for gastric varices with gastrosplenic or gastrosplenic collaterals. *AJR Am J Roentgenol* 1996;167:1317-20.
- Hirota S, Matsumoto S, Tomita M, et al. Retrograde transvenous obliteration of gastric varices. *Radiology* 1999;211:349-56.
- Akahane T, Iwasaki T, Kobayashi N, et al. Changes in liver function parameters after occlusion of gastrosplenic shunts with balloon-occluded retrograde transvenous obliteration. *Am J Gastroenterol* 1997;92:1026-30.
- Hiraga N, Aikata H, Takaki S, et al. The long-term outcome of patients with bleeding gastric varices after balloon-occluded retrograde transvenous obliteration. *J Gastroenterol* 2007;42:663-72.

27. Kamezaki H, Maruyama H, Shimada T, Takahashi M, Okugawa H, Yokosuka O. Short- and long-term clinical outcome after B-RTO: Is pretreatment portal flow direction a predictive factor? *Hepatol Int* 2013;7(1):241-47.
28. Shimoda R, Horiuchi K, Hagiwara S, et al. Short-term complications of retrograde transvenous obliteration of gastric varices in patients with portal hypertension: Effects of obliteration of major portosystemic shunts. *Abdom Imaging* 2005;30:306-13.
29. Nishida N, Ninoi T, Kitayama Y, et al. Selective B-RTO of gastric varix with preservation of major portacaval shunt. *AJR Am J Roentgenol* 2006;186:1155-57.
30. Chikamori F, Kuniyoshi N, Kawashima T, Takase Y. Gastric varices with gastroduodenal shunt: combined therapy using transjugular retrograde obliteration and partial splenic embolization. *AJR Am J Roentgenol* 2008;191:555-59.
31. Koizumi J, Hashimoto T, Myojin K, Itou C, Kagawa T, Nishibe T, et al. Balloon-occluded retrograde transvenous obliteration of gastric varices: Use of CT-guided foam sclerotherapy to optimize technique. *AJR Am J Roentgenol* 2012;199:200-07.
32. Choi SY, Won JY, Kim KA, Lee do Y, Lee KH. Foam sclerotherapy using polidocanol for balloon-occluded retrograde transvenous obliteration (B-RTO). *Eur Radiol* 2011;21:122-29.

## ABOUT THE AUTHORS

### Hitoshi Maruyama

Department of Gastroenterology and Hepatology, Chiba University Graduate School of Medicine, Chiba, Japan

**Correspondence Address:** 1-8-1, Inohana, Chuo-ku, Chiba 260-8670, Japan, Phone: 81-432262083, Fax: 81-432262088 e-mail: maru-cib@umin.ac.jp

### Osamu Yokosuka

Department of Gastroenterology and Hepatology, Chiba University Graduate School of Medicine, Chiba, Japan