

A Case Report of Hepatic Tuberculosis

¹Mamun-Al-Mahtab, ¹Salimur Rahman, ²Mohammad Kamal

¹Department of Hepatology, Bangabandhu Sheikh Mujib Medical University, Dhaka, Bangladesh

²Department of Pathology, Bangabandhu Sheikh Mujib Medical University, Dhaka, Bangladesh

Correspondence: Mamun-Al-Mahtab, Assistant Professor, Department of Hepatology, Bangabandhu Sheikh Mujib Medical University Dhaka, Bangladesh, Phone: +880-2-8850371, +880-1711567275, Fax: +880-2-8826840, e-mail: shwapnil@agni.com

ABSTRACT

Background: Pulmonary tuberculosis (TB) is one of the common infections in developing countries of Asia and Africa, however, little is known about hepatic tuberculosis from these countries.

Case report: We report a case of hepatic tuberculosis in a 24-year-old Bangladeshi man. He attended the physician for evaluation of hepatitis B surface antigen. He was asymptomatic with no notable hepatic and pulmonary complains. A diagnosis of hepatic TB was made after evaluation of liver histology that exhibited epithelioid granuloma with central caseating necrosis in the liver. The patient was successfully treated by antitubercular drugs.

Discussion: Involvement of liver in TB may occur in a variety of forms. The commonest form is disseminated tuberculosis. A second variety represents diffuse involvement of liver with granuloma formation (granulomatous hepatitis). This is the first reporting of hepatic TB from Bangladesh, a country that harbors millions of people infected with TB and hepatitis viruses.

Abbreviations: TB—Tuberculosis; HBV—Hepatitis B virus; HBsAg—Hepatitis B surface antigen; HAI—Histology activity index; AFB—Acid fast bacilli.

Keywords: Hepatic tuberculosis, Caseating necrosis, Bangladesh.

INTRODUCTION

Tuberculosis (TB) is a common infection in developing countries of Asia and Africa. Though pulmonary TB is the most frequent presentation, extrapulmonary diseases involving lymph nodes, terminal ileum and peritoneum are not infrequent. Hepatic involvement has been described in 90% of miliary TB, 75% of extrahepatic TB and 25% of pulmonary TB.¹ Presenting symptoms in these settings are mainly those of miliary tuberculosis.²

Essop et al have shown that hepatic TB may account for about 1.2% of all TB diagnosed at general hospital.³ However, isolated hepatic TB without disseminated disease is rare.² High index of suspicion is required for correct diagnosis and it may only be diagnosed on histopathological examination of liver biopsy specimens. This becomes even harder when the patients exhibit no clinical symptoms.

We report a case of isolated hepatic TB that was otherwise asymptomatic and incidentally diagnosed on liver biopsy during elaborative assessment of chronic hepatitis B virus infection of the patient.

CASE REPORT

A 24-year-old Bangladeshi gentleman from middle socioeconomic background was evaluated for chronic hepatitis B virus (HBV) infection. He was expressing hepatitis B surface antigen (HBsAg) in the sera. However, he was

free from any subjective symptom of liver disease or any biochemical marker suggesting liver injury. He did not give any history suggestive of fever, night sweats, lassitude, loss of appetite or weight loss. He did not have any past history of diabetes or repeated infections. He also did not give history of contact with open case of TB. His personal history did not reveal any high-risk behavior that may cause TB. On investigation, he was expressing HBsAg and hepatitis B e-antigen in the sera and the level of HBV DNA was 5.5×10^5 copies/ml. However, serum bilirubin (0.9 mg/dl) and alanine aminotransferase (32 IU/L) and prothrombin time (13 seconds) were within normal limits. The level of hemoglobin was 15 gm/dl. Ultrasound examination showed slightly coarse echotexture of the liver (Fig. 1). The radiographic finding of the chest was inconclusive.

As the levels of HBV DNA were high and the echogenicity of the liver was slightly coarse, liver biopsy was performed using 14G tru-cut needle and 1.5 cm liver tissue was obtained. Macroscopic assessment of liver biopsy did not reveal any abnormality. On microscopic examination, epithelioid granuloma with central caseating necrosis suggestive of tubercular granuloma was seen in the liver (Fig. 2). Mild intralobular degeneration and periportal inflammation were also seen but with no significant fibrosis. Histological activity index (HAI) score was two according to the classification of Knodell et al.⁴

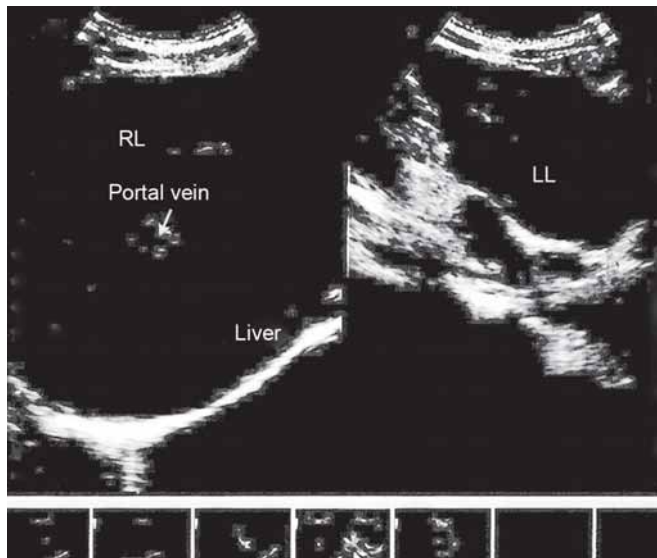


Fig. 1: USG of hepatobiliary system of patient showing coarse hepatic echotexture

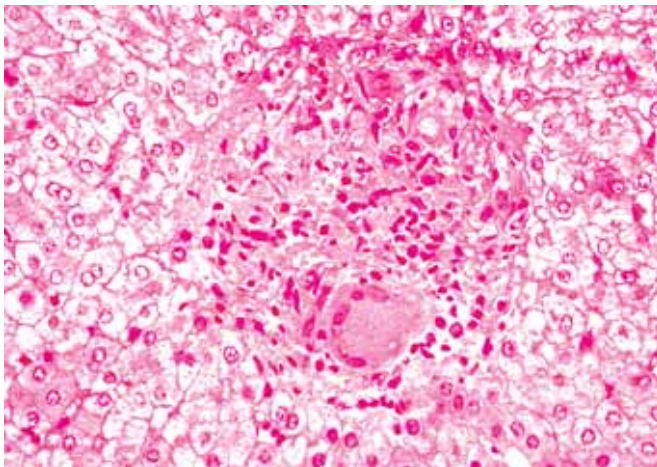


Fig. 2: Hepatic histopathology of patient showing granuloma (H&E)

On the basis of histological features, diagnosis of hepatic TB was made and the patient was treated with antitubercular therapy containing streptomycin, isoniazid and ethambutol. There was no incidence of hepatotoxicity due to consumption of anti-TB drugs and he completed the full course of therapy.

DISCUSSION

Involvement of liver in tuberculosis can occur in a variety of forms.⁵ The commonest one is being a part of disseminated TB. Second variety is that of diffuse involvement of liver with granuloma formation called granulomatous hepatitis. Pulmonary involvement is not usually seen in granulomatous variety. In a rare third variety, granulomatous lesions coalesce to form tuberculoma. They may undergo caseation and liquefaction giving appearance of an abscess. This form is also termed as local hepatic TB.

In all of these forms the patients are usually symptomatic and associated with a number of laboratory abnormalities. When associated with miliary tuberculosis, patients usually presents with pyrexia of unknown origin and minimal or no symptoms pertaining to liver.² In granulomatous form, fever is accompanied by hepatomegaly, splenomegaly and abdominal pain.² In case of hepatic tuberculoma, a palpable lump may be present in the liver and is often confused with abscess.⁶ In miliary and granulomatous forms, the most remarkable laboratory finding is elevation of alkaline phosphatase. Serum transaminases are also modestly increased.⁷ Hyperbilirubinemia is uncommon and in its presence portal adenopathy compressing the bile ducts or alternative diagnoses should be considered. Imaging techniques are not helpful in diagnosing isolated hepatic tuberculosis other than those forming tuberculoma as the size of lesion is very small (< 2 mm).² Liver biopsy is usually required. In histopathology, finding of hepatic granuloma with central caseating necrosis on biopsy is characteristic and should be considered diagnostic of tuberculosis until proven otherwise.⁷ However, other etiology like sarcoidosis, primary biliary cirrhosis, drugs should also be kept in mind. In fact, hepatic granuloma in tuberculosis endemic region is highly suggestive of hepatic tuberculosis.⁸ Empirical treatment with antitubercular therapy is often warranted. Demonstration of acid fast bacilli (AFB) in liver biopsy specimen always proves etiology to be tubercular. AFB was demonstrated in liver biopsy specimen in 0 to 59% of patients.² For unknown reasons, in reports from Indian subcontinent describing AFB positivity are scanty.² Culture of liver tissue for *Mycobacterium tuberculosis* and PCR are other techniques required for confirming hepatic tuberculosis.

Asymptomatic presentation is not a normal mode of presentation of hepatic TB, as shown in this case report. This case was detected incidentally on liver biopsy, which was done for evaluation of chronic hepatitis B virus infection. Usually patients would be symptomatic for at least one to two years before diagnosis of hepatic TB. Though tubercular bacilli were not found in this case, caseating granuloma provided a strong support of a tubercular etiology. Mantoux test showed strong positivity that supported the present diagnosis. Absence of history of drugs, absence of cholestatic features, athralgia, hilar nodes on chest X-ray made diagnosis of drug-induced hepatic granuloma, primary biliary cirrhosis and sarcoidosis unlikely.

The patient was treated with antitubercular therapy with three drugs mentioned above but avoiding pyrazinamide and rifampicin for there potential hepatotoxicity. The treatment response was difficult to assess as the patient did

not have any symptoms pertaining to tuberculosis at presentation. However, he did not develop any hepatotoxicity or any other complication with full course of antitubercular medication and is currently under follow-up for both hepatic TB and HBV infection and is leading a healthy life. There is paucity of information about hepatic TB in patients infected with hepatitis viruses. Although we are not sure about a role of HBV in acquisition or progression of hepatic TB in this patient, this study has exposed a situation that deserves histopathological assessment of liver biopsy not only for liver damages but also for other pathological focuses including TB.

Tuberculosis is well-known for its ability to present with myriads of manifestations, sometimes challenging acumen of astute physicians. But seedling of liver tissue with TB without producing any notable symptom can occur without any clinical feature; the pathological significance of which should be explored.

REFERENCES

1. Klatskin G. Hepatic granulomata: Problems in interpretation. *Mt Sinai J Med* 1977;44:798-812.
2. Puri AS, Nayyar AK, Vij JC. Hepatic Tuberculosis. *Ind J Tub* 1994;4:131-34.
3. Essop AR, Posen JA, Hodgkinson JH, Segal I. Tuberculosis hepatitis: A clinical review of 96 cases. *Quart J Med* 1984;53: 465-77.
4. Knodell RG, Ishak KG, Black WC, et al. Formulation and application of a numerical scoring system for assessing histological activity in asymptomatic chronic active hepatitis. *Hepatology* 1981;1:431-35.
5. Spiegel CT, Tuczon CU. Tuberculosis liver abscess. *Tubercle* 1984;65:127.
6. Bangroo AK, Malhotra AS. Isolated hepatic tuberculosis. *J Indian Assoc Pediatr Surg* 2005;10:105-07.
7. Albrecht H. Bacterial and miscellaneous infections of the liver. In: Zakim D, Boyer TD (Eds). *Hepatology A text book of liver diseases*. Philadelphia: WB Saunders 2003:1109-21.
8. Alvarez SZ, Carpio R. Hepatobiliary tuberculosis. *Dig Dis Sci* 1983;28:193.